

CASE REPORT

Asymptomatic Disseminated Tuberculosis as a Cause of Sudden Death in an Immunocompetent Serving Soldier Diagnosed at Autopsy: A Case Report

¹Khushi R Rathi, ²Kavita Sahai, ³Sharmila Dudani, ⁴Vandana Gangadharan, ⁵Archana Rautela, ⁶Rachna Gulati

ABSTRACT

We present a case of disseminated tuberculosis (DTB) in a young serving soldier with no prior medical history and admitted with respiratory symptoms of short duration. Tuberculosis (TB) was not suspected on examination. Investigations revealed anemia, relative neutrophilia, and a deranged coagulation profile. He died within six hours of admission. An autopsy revealed evidence of TB in the lungs, kidney, lymph nodes, liver, spleen and bone marrow. This case highlights the importance of recognizing this disease, especially in endemic, resource-limited settings.

Keywords: Asymptomatic, Disseminated tuberculosis, Immunocompetent,

How to cite this article: Rathi KR, Sahai K, Dudani S, Gangadharan V, Rautela A, Gulati R. Asymptomatic Disseminated Tuberculosis as a Cause of Sudden Death in an Immunocompetent Serving Soldier Diagnosed at Autopsy: A Case Report. *Journal of Medical Academics* 2018;1(1):58-60.

Source of support: Nil

Conflict of interest: None

INTRODUCTION

Disseminated TB refers to the concurrent involvement of at least two noncontiguous organs of the body or involvement of the blood or bone marrow by the tubercular process.¹

Though only 5 to 10% of immuno-competent individuals are susceptible to TB it is a major cause of death worldwide. Recent estimates published by World Health Organization (WHO) put the disease burden at 9.6 million cases and 1.5 million deaths worldwide.²

Since the clinical presentation is often nonspecific, and therefore the diagnosis of DTB may be difficult and delayed³ or occasionally possible only on autopsy.⁴

We report a case of DTB in an immuno-competent

serving soldier in whom the disease was largely asymptomatic. The patient presented with a short history of fever and breathlessness and died within six hours of admission. Diagnosis of DTB was confirmed by histopathological examination of the organs at autopsy. This case underscores the need to maintain a high degree of clinical suspicion for antemortem diagnosis, so that appropriate treatment can be instituted to avoid preventable mortality.

CASE REPORT

A 28-year-old serving soldier was admitted to a Garrison hospital with a history of fever and breathlessness of 10 days duration. He also had a history of a cough with expectoration of 1-month duration. The patient has been well and discharging his duties before this. He had no H/O of alcohol, smoking, drug intake, diabetes mellitus or any immunological disorder. There was no significant past medical history. On examination, he was poorly nourished. Pulse-118/minute, BP-120/70 mmHg. Respiratory rate was 28/minute and SPO2 was 60%. There was Rt. Cervical lymphadenopathy along with bilateral coarse crepitations in the lungs. Preliminary investigations done in the emergency side lab revealed hemoglobin of 7.7 gm%, Total Leukocyte count-4,800/cmm. The differential count revealed relative neutrophilia.

Platelets were adequate on smear. PT was 20/13 sec and PTTK was 38/30 sec. Rapid tests for human immunodeficiency virus (HIV), hepatitis B surface antigen (HBsAg), and hepatitis C virus (HCV) were negative. X-ray chest revealed bilateral reticulonodular opacities. The patient was started on broad-spectrum antibiotics, but he developed cardiac arrest and died within 6 hours of admission. No further investigations could be done. At autopsy, the lungs were congested and firm on palpation. There were tiny 1 to 2 mm well-circumscribed nodules scattered all over the lungs suggestive of bronchopneumonia. Pleura appeared unremarkable. The peritoneal cavity and all other organs were also unremarkable on gross examination. Post-mortem examination of cerebrospinal fluid (CSF) revealed a lymphocytic pleocytosis. Samples sent for bacterial culture from blood, pericardial,

^{1,3}Professor, ²Professor and HOD, ^{4,5}Assistant Professor, ⁶Tutor

¹⁻⁶Department of Pathology, Army College of Medical Sciences and Base Hospital, Delhi Cantonment, India

Corresponding Author: Sharmila Dudani, Professor, Department of Pathology, Army College of Medical Sciences and Base Hospital, Delhi Cantonment, India, e-mail: drsdudani@hotmail.com

pleural and peritoneal fluids showed no growth. Mycobacterial cultures, however, could not be done.

Microscopic examination revealed multiple discrete caseating epithelioid granulomas in the liver, spleen, lungs kidney, bone marrow, mediastinal and abdominal lymph nodes. (Figs 1 to 4). AFB was positive for *M. Tuberculosis*. The lungs, in addition, showed a dense mixed inflammatory infiltrate in the alveoli. Based on the autopsy findings, a post-mortem diagnosis of disseminated tuberculosis was confirmed.

DISCUSSION

Tuberculosis is a broad spectrum disease that can involve both pulmonary and extrapulmonary sites. While pulmonary TB is the commonest, dissemination to extrapulmonary sites like lymph nodes, meninges, bone, pleura, pericardium, peritoneum, liver, spleen, gastrointestinal tract, genitourinary tract and skin can occur. Extrapulmonary involvement is seen in 20% of tuberculosis patients especially those who are immunosuppressed.⁵

The global burden of tuberculosis is rising, due to comorbidities like diabetes mellitus, HIV infection,

cardiovascular diseases, increasing use of immunosuppressive therapy and is an important cause of morbidity and mortality in these patients.⁶ DTB is rare in immunocompetent hosts with a reported incidence of 2.8%.⁷

Though fever and weight loss are the commonest presenting symptoms, they may be nonspecific and obscure. Anemia, hypoalbuminemia, raised erythrocyte sedimentation rate (ESR) and Lactate Dehydrogenase (LDH) levels the commonest findings, but these are not consistently present leading to delays in diagnosis and initiation of therapy.^{6,8} Our patient though presenting with fever, breathlessness, and anemia; the short duration of symptoms along with tachycardia, decreased SpO₂, coarse crepitation in lungs, relative neutrophilia on a complete blood count examination and the deranged coagulation profile suggested an infective process with impending disseminated intravascular coagulation (DIC).

Miliary shadowing is seen only in 29% of patients' on X-ray and also lacks the sensitivity and specificity for disseminated tuberculosis⁸ with almost 13% of patients' having normal findings on X-ray.⁶

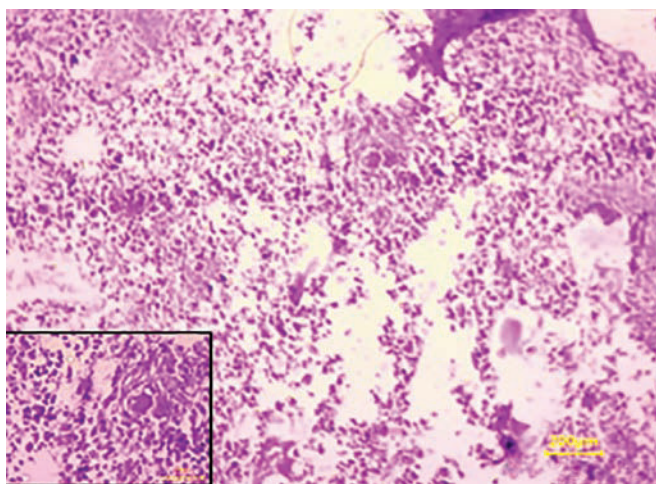


Fig. 1: Granuloma in bone marrow 100x H and E. inset : epithelioid cells with langhans' giant cells

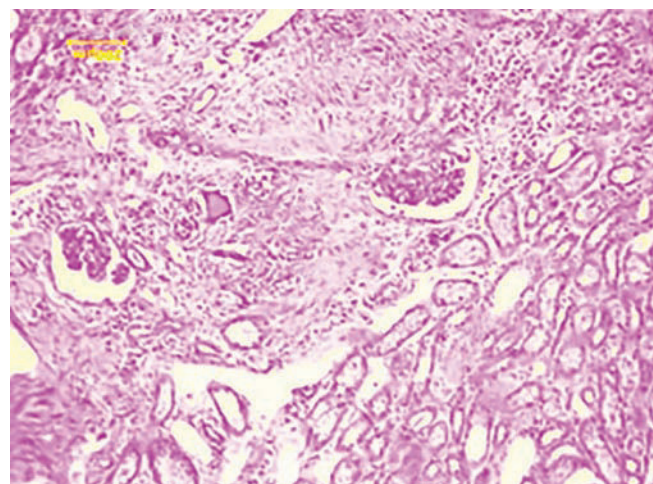


Fig. 2: Granuloma in kidney with giant cell 400X H and E

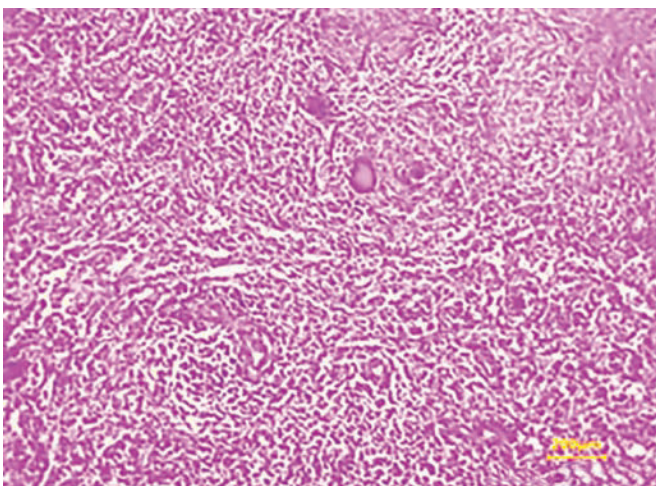


Fig. 3: Granuloma in Spleen 400X H&E

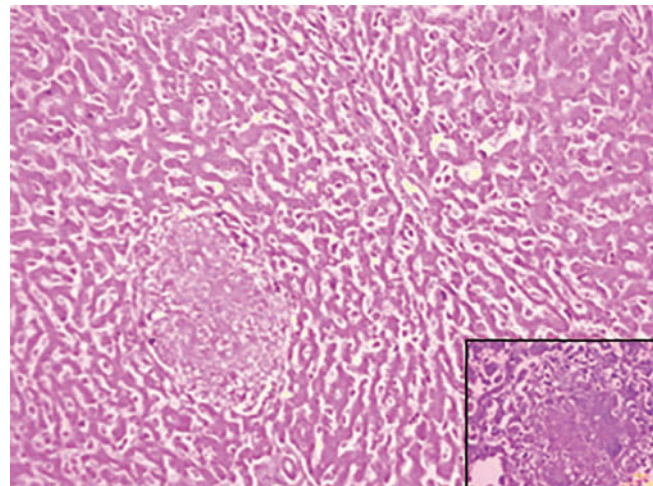


Fig. 4: Granuloma in Liver with giant cells (inset)

Mycobacterial blood cultures may play an important role in contributing to the diagnosis of DTB. The sensitivity of blood culture is comparable to bone marrow culture and also, is also safer and less invasive.⁹

Diagnosis of mycobacterial infection can be clinically challenging especially in endemic areas and must be pursued aggressively. Despite recent advances in clinical and laboratory methods, diagnosis of mycobacterial infection may be delayed even today due to the varied and nonspecific symptoms and findings. In such cases, the diagnosis must rely heavily on the interpretation of a constellation of clinical features especially in endemic, resource-limited settings,^{10,11} not only to reduce the global burden of TB but also avoid the diagnosis on autopsy as in the present case.

REFERENCES

1. Iseman MD. Extrapulmonary tuberculosis in adults. In: Clinician's guide to tuberculosis. 1st ed. Philadelphia. Lippincot Williams and Wilkins. 2000;145-97.
2. Global Tuberculosis control. WHO report 2015. WHO/ HTM/ TB 2015.22. Geneva. World Health Organization; 2015.
3. Grieco MH, Chmel H. Acute disseminated tuberculosis as a diagnostic problem : a clinical study based on twenty eight cases. *Am Rev Respir Dis* 1974;109:554-60.
4. Chapman CB, Whorton CM. Acute generalized military tuberculosis in adults. – A clinicopathological study based on sixty three cases diagnosed at autopsy. *N Engl J Med* 1946;235-248.
5. Gavazzi G, Bouchard O, Bosseray A, Lecierq P, Micoud M. Cerebral and pulmonary miliary tuberculosis in an immunocompetant patient : aggravation in an adequately treated patient. *Presse Med* 1998;27:958-62.
6. Crump JA, Reller JB. Two decades of disseminated tuberculosis at a University Medical Center. The expanding role of mycobacterial blood culture. *Clin Infect Dis* 2003;37:1037-43
7. Charfi MR, Douqui MH, Louzir B, Mestiri A, Zbiba M, Belagia MS, Daghfous J. Disseminated tuberculosis in non immunocompromised host : three case reports. *Rev Med Interne* 1998; 19:917-20.
8. Sharma SK, Mohan A, Sharma A. Miliary tuberculosis. A new look at an old foe. *Journ of Clin.Tuberculosis and other Mycobacterial diseases* 2016;3:13-27.
9. Long RO, Connor R, Palayew M, Hershfield E, Manfreda J. Disseminated tuberculosis with and without miliary pattern on chest radiograph : a clinical-pathological radiological correlation . *Int J Tuberc Lung Dis* 1997;1:52-8.
10. Wang JY, Hsueh PR, Wang SK, Jan IS, Lee LN, Liaw YS et al. Disseminated tuberculosis : a 10 year experience in a medical center. *Medicine (Baltimore)* 2007;86:39-46.
11. Harries AD. Unrecognised mycobacterium tuberculosis {Letter} *Lancet* 2000;355:142.