

Anomalies of Anterior Belly of Digastric Muscle in Cadavers from South India

¹Suman Verma, ²Sulochana Sakthivel, ³Aravindhan Kishore

ABSTRACT

Aim: Anterior belly of digastric muscle forms the boundary of submental and submandibular triangles, and is an important surgical landmark of the suprahyoid region. It attaches above to the digastric fossa on the mandible and below to the intermediate tendon of the muscle.

Materials and methods: Thirty formalin-embalmed cadavers were examined for variations in the anterior belly of digastric muscle.

Results: Anomalous muscles were seen in two cases (6.6%), one unilateral and one bilateral. Anterior belly of digastric muscle was absent on the left side in one cadaver. Symmetrical appearance of accessory muscles, medial and parallel to the main bellies was noted in the bilateral case.

Conclusion: Variations in the anterior belly like the presence of accessory fibers or absence of the anterior belly alter the anatomic layout of the region between the mandible and hyoid bone, which is relevant for clinicians, surgeons, and radiologists dealing with the suprahyoid area.

Clinical significance: Atypical anterior belly of digastric muscle is likely to affect the movements of joints involving mandible and hyoid, surgical interventions in the suprahyoid region, and the interpretation of diagnostic scans.

Keywords: Accessory muscle, Anterior belly, Digastric muscle, Suprahyoid.

How to cite this article: Verma S, Sakthivel S, Kishore A. Anomalies of Anterior Belly of Digastric Muscle in Cadavers from South India. *J Med Acad*, 2018;1(2):91-93.

Source of support: Nil

Conflict of interest: None

INTRODUCTION

Digastric muscle is a suprahyoid muscle seen between the hyoid bone and mandible. It has acquired its name due to the two bellies forming it. An intermediate tendon joins the two bellies of the digastric muscle. Anterior belly of digastric muscle (ABD) forms a boundary for the

submental and submandibular triangles. ABD attaches above to the digastric fossa on the mandible and below to the intermediate tendon of the muscle.¹

Multiple case reports have presented variations in ABD, like double anterior belly,² a fusion of accessory muscles with mylohyoid raphe,³ bilaterally symmetrical extra muscles,⁴ an extra belly between two anterior bellies,⁴ bilateral accessory muscles with common insertion on hyoid,⁵ and accessory bellies forming a cruciate pattern.^{6,7}

Anomalies of the anterior belly are classified according to the location and number of accessory bellies. De-Ary-Pires et al. classified the muscle into five types. Type I is the typical and most common presentation. Extra two, three and four bellies are seen in types II, III and IV, respectively.⁸

The digastric muscle becomes trigastric if an extra-muscle slip is seen with the anterior belly.⁹ Monogastric muscle is a rarely encountered arrangement, where the anterior belly is absent.⁸

Anterior belly depresses the mandible when acting from below and elevates the hyoid acting from above. Injecting botulinum into ABD is helpful in correcting jaw occlusion abnormalities following mandible fractures.¹⁰ The presence of accessory anterior bellies can possibly affect such interventions and should be ruled out beforehand.¹¹ In cases with paralysis of muscles due to loss of marginal mandibular nerve, anterior belly transfer to lower lip is employed.¹² Variations in anterior bellies range from 5.9 to 73%.¹³ Awareness of ABD anomalies is important for the surgeons operating in the cervical or submandibular region.⁸ Currently, there is a deficiency of sufficient information on ABD anomalies in the south Indian population, and this study aims to fulfill these lacunae.

MATERIALS AND METHODS

This was an observational study carried out on 30 human cadavers (23 males, 7 females) taken from the Department of Anatomy, JIPMER. All the cadavers were approved for use in scientific research. The specimens were formalin embalmed and preserved in 10% formalin. The average age of cadavers was 60 years (54–69 years). No signs of trauma or surgery were evident on external inspection. For each cadaver, a midline incision was placed extending from mandible to manubrium. This was joined by hori-

^{1,2}Associate Professor, ³Professor and Head

¹⁻³Department of Anatomy, Jawaharlal Institute of Postgraduate Medical Education and Research, Puducherry, India

Corresponding Author: Sulochana Sakthivel, Associate Professor, Department of Anatomy, Jawaharlal Institute of Postgraduate Medical Education and Research, Puducherry, India, e-mail: ssana.j210@gmail.com

zontal incisions along the base of mandible and clavicle. After reflection of skin and superficial fascia, ABD was identified between the mandible and hyoid bones. Any variation in the anterior belly was identified, recorded and photographed.

RESULTS

The ABD anomalies were seen in two male cadavers (6.6%). The bilateral and unilateral variations were present in one cadaver each. The first case was bilaterally symmetrical in which an accessory muscle was present medial and parallel to the main bellies. On both sides, it was attached to the lower border of the mandible and upper margin of the body of the hyoid bone (Fig. 1). Each muscle was broad, flattened, and its inferomedial part was tendinous. Few of the tendinous fibers from its lower lateral part joined with the main anterior belly. We identified this accessory muscle as the third head of the digastric muscle. The accessory muscle on the right side was broader, thinner and less tendinous than that of the left side. Both accessory muscles received innervation from the nerve to mylohyoid from their inner aspect. The main anterior belly had typical attachments.

Unilateral absence of anterior belly on the left side was identified in the second case. A little above the hyoid bone, a thin intermediate tendon fused with the lower part of mylohyoid muscle (Fig. 2). Hypertrophied mylohyoid muscle on the left side was unambiguous. The anatomic arrangement on the right side was typical. This presentation was recorded as digastric on the right and monogastric on the left.

DISCUSSION

Digastric muscle has two bellies, and variations in the anterior belly are commonly encountered in literature.¹³ Mangalgiri et al. studied ABD muscle in 15 cadavers

and reported variation in six (40%). In their study, the number of unilateral and bilateral variations was the same, and none of the bilateral variations were symmetrical. Also, the accessory muscles were usually placed obliquely and mostly attached to the mylohyoid muscle or its median raphe.¹⁴ We observed an equal number of unilateral and bilateral cases in our study, but the bilateral variation was symmetrical. A study by Liquidato et al. also reported an equal number of unilateral and bilateral variations. In bilateral cases, accessory bellies were medial to the main bellies and took insertion on the mylohyoidraphae or crossed the midline to attach to the intermediate tendon.⁹ The anomalies in the present study do not match any of the variations reported by Mangalgiri et al. and Liquidato et al.^{9,14} The first case in our study matches the type II variation mentioned in De-Ary-Pires et al.⁸ A similar account of bilateral and symmetrical accessory anterior bellies has appeared in a report by Bakirci et al.⁴ De-Ary-Pires et al., reported the incidence of ABD variations as 8.1%, whereas, Fujimura et al., found it to be 24.1%.^{8,15} Sargon et al., observed anomalous ABD, in 5%.¹⁶ The incidence from our study is close to the incidence in Sargon et al. and De-Ary-Pires et al., and much less than that in Mangalgiri et al. and Fujimura et al.^{8,14-16}

We observed bilaterally symmetrical accessory bellies, medial and parallel to the main bellies. The accessory bellies can also be lateral and parallel to the main anterior bellies on both sides.¹⁷ Uzun et al. reported a case with bilateral accessory muscles, which were parallel and medial to anterior bellies, and formed a single tendon going to the hyoid bone.⁵ There have been reports in the literature of bilateral accessory bellies crossing each other in the midline forming a letter 'X'.^{6,7}

In embryonic life, ABD develops from one of the pharyngeal arches. The first pharyngeal arch initially appears in a 22-day embryo. The myoblasts from the paraxial

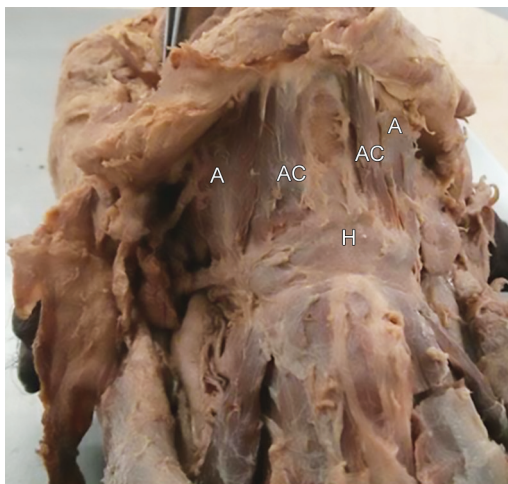


Fig. 1: Superficial dissection of suprahyoid region. A: Anterior belly of digastric; Ac: Accessory belly; H: Body of hyoid bone

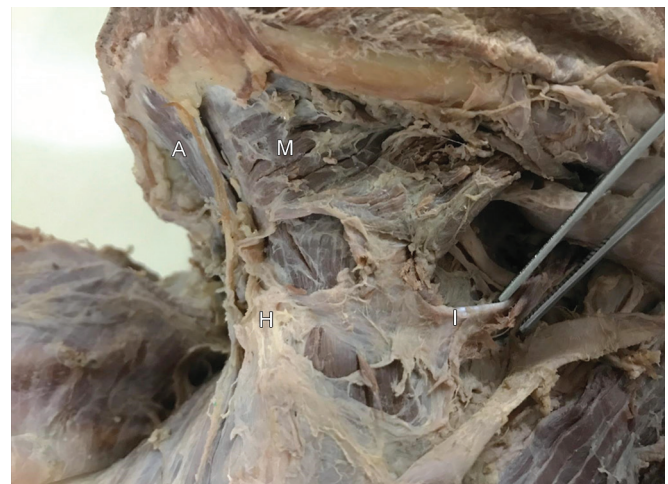

Fig. 2: Unilateral absence of anterior belly of digastric. A: Anterior belly of digastric; H: Hyoid bone; M: Mylohyoid; I: Intermediate tendon

mesoderm of this arch form ABD and mylohyoid muscles. Both the muscles get their innervation from the nerve of the first arch, mandibular nerve.¹⁸ Further, defects in mesoderm development could lead to variations in ABD. Problems rooted in the neural crest migration in the first pharyngeal arch would lead to the formation of the accessory belly.³ Since ABD and mylohyoid muscles develop from the same pharyngeal arch, and lie in close proximity, the fibers from the two muscles sometimes join with each other to a variable extent,^{13,16} such arrangement was noted in the unilateral variation from our study.

Accessory bellies are commonly seen as compared to the absence of anterior belly.⁸ In a study on 74 cadavers by De-Ary-Pires et al., only one case of unilateral absence of ABD was seen.⁸ Sargon et al. also observed a unilateral case of anterior belly absence on the left side.¹⁶ Mentohyoid or Macalister muscle is considered as the separate part of the digastric muscle, which attaches to the mandible and hyoid bones, and is seen on the medial side of the anterior belly.^{8,13}

Asymmetric or unilateral anomalies in ABD may affect the biomechanics of jaw, hyoid, larynx.⁹ Digastric muscle depresses mandible and plays a significant role in the movements of the jaw during mastication.¹ It has been seen that the botulinum toxin injection in the anterior belly muscle amends the open anterior bite due to bilateral mandible angle fracture.¹⁰ Understanding of ABD variations is essential for the success of such procedures.¹¹ ABD forms the boundary of the submandibular triangle and forms an important surgical landmark during surgery in this area.⁹ Unilateral variation like the absence of ABD are likely to be significant in such cases.

CONCLUSION

The ABD like accessory fibers or absence of muscle would modify the topography of the region between the mandible and hyoid bone, and would possibly affect the interventions in the suprahyoid area.

CLINICAL SIGNIFICANCE

These accessory muscles have both surgical and radiological significance. In surgeries for malignant tumors in the suprahyoid region, the presence of these muscles will affect the exposure of surgical area and can be confused with tumors.³ Awareness of such muscle variations is also important for the interpretation of diagnostic scans. Report of digastric muscle variations is important due to its clinical significance for surgeons and radiologists.

REFERENCES

1. Watkinson JC, Gleeson M. Neck. In: Standring S, editor. *Gray's anatomy: The anatomical basis of clinical practice*. 41st edition. Elsevier;2016: 449.
2. Zdilla MJ, Soloninka HJ, Lambert HW. Unilateral duplication of the anterior digastric muscle belly: a case report with implications for surgeries of the submental region. *J Surgcase Rep*. 2014;12:1-2.
3. Loukas M, Louis RG, Kapos T, Kwiatkowska M. A case of bilateral accessory digastric muscle. *Folia Morphol*. 2005 May;64(5):233-236.
4. Bakrici S, Kafa IM, Uysal M, Sendemir E. Anterior belly anomalies of the digastric muscle: case report. *Eur J Anat*. 2007;11(3):201-203.
5. Uzun A, Aluclu A, Kavakli. Bilateral accessory anterior bellies of the digastric muscle and review of literature. *AurisNasus Larynx*. 2001;28:181-183.
6. Mascaro MB, Picoli LC, Santos FM, Bonsi AB, Souza MR, Prosdociami FC. Anatomical variation of the anterior belly of the digastric muscle: case report and clinical implications. *J Morpho Sci*. 2011; 28: 72-75.
7. Atkekin M, Kurtoglu Z, Ozturk AH. A bilateral and symmetrical variation of the anterior belly of the digastric muscle. *Acta Med Okayama*. 2003;57:205-207.
8. De-Ary-Pires B, Ary-Pires R, Pires-Neto MA. The human digastric muscle: Patterns and variations with clinical and surgical correlations. *Ann Anat*. 2003;185:471-479.
9. Liquidato BM, Barros MD, Alves AL, Pereira CSB. *Int J Morphol*. 2007;25:797-800.
10. Seok H, Park YT, Kim SG, Park YW. Correction of post-traumatic anterior open bite by injection of botulinum toxin type A into the anterior belly of the digastric muscle: case report. *J Korean Assoc Oral Maxillofac Surg*. 2013;39:188-192.
11. Zdilla MJ. Screening for variations in anterior digastric musculature prior to correction of post-traumatic anterior open bite by injection of botulinum toxin type A: a technical note. *J Korean Assoc Oral Maxillofac Surg*. 2015;41:165-167.
12. Tan ST. Anterior belly of digastric muscle transfer: a useful technique in head and neck surgery. *Head and Neck: Journal for the Sciences and Specialties of the Head and Neck*. 2002;24(10):947-954.
13. Bergman RA, Afifi AK, Miyauchi R. *Illustrated encyclopedia of human anatomic variation: opus I: muscular system: alphabetical listing of muscles. Psoas Minor*. Viewed from <http://www.anatomyatlases.org/AnatomicVariants/MuscularSystem/Text/P/Psoas.shtml> (accessed in July, 2014). 2015.
14. Mangalagiri A, Razvi MRA. Variations in the anterior belly of digastric. *Int J health Sci*. 2009;3:257-262.
15. Fujimura A, Onodera M, Feng XY, Osawa T, Nara E, Nagato S, et al. Abnormal anterior belly of the digastric muscle: a proposal for the classification of abnormalities. *Anatomical science international*. 2003;78(3):185-188.
16. Sargon MF, Onderoglu S, Surucu HS, Bayramoglu A, Demiryurek D, Ozturk H. Anatomic study of complex anomalies of the digastric muscle and review of literature. *Okajimas Folia Anat Jpn*. 1999;75:305-314.
17. Holibkova A, Machalek L. A report on anomalies of digastric muscle. *ActaUnivPalackiOlomucFac Med*. 1999;142.
18. Schoenwolf GC, Bleyl SB, Brauer PR, Francis-West PH. *Larsen's human embryology*. 5th edn. Elsevier. Philadelphia. P- 440, 445.